

CHAPTER

17

Idiopathic Giant Cell Myocarditis

Leslie T. Cooper, Jr., M.D.

INTRODUCTION

MECHANISMS OF GIANT CELL MYOCARDITIS

DIAGNOSTIC STRATEGY

TREATMENT OF GIANT CELL MYOCARDITIS

THE GIANT CELL MYOCARDITIS TREATMENT TRIAL

CONCLUSIONS

INTRODUCTION

Idiopathic giant cell myocarditis (IGCM) was first described by Saltykow¹ in a 37-year-old man who died suddenly after surgical drainage of an abscess. Since then, dozens of case reports and a few small series have documented that IGCM is a usually fatal disorder that generally affects young otherwise healthy individuals, although a minority of cases occur in association with autoimmune disorders or thymoma. From 1905 until 1987, all cases were described at autopsy, and survival was generally less than 3 months from symptom onset. In 1993, Ren et al.² described prolonged transplant-free survival in 3 patients with IGCM. Several patients whose disease was diagnosed by endomyocardial biopsy survived 1 or more years in association with immunosuppressive treatment.³ This chapter reviews the pathophysiology, natural history, proposed diagnostic strategy, and treatment options for IGCM.

In the first half of the twentieth century, the term “giant cell myocarditis” was used to describe both granulomatous and diffuse inflammatory myocardial infiltrates that contained multinucleated giant cells.⁴⁻⁶ Idiopathic granulomatous myocarditis with giant cells was described in several case reports as cardiac sarcoidosis or giant cell myocarditis.⁷⁻⁹ Tesluk¹⁰ first distinguished the well-organized, granulomatous lesions of cardiac sarcoidosis from a diffuse, nongranulomatous infiltrate, which he called giant cell myocarditis. Most authorities since have considered giant cell myocarditis as a distinct clinical and pathologic entity rather than a virulent form of isolated cardiac sarcoidosis.¹¹⁻¹³ This distinction does not result from a proven mechanistic difference between these disorders. Indeed, about half of the cases of cardiac sarcoidosis are isolated, with no evidence of extracardiac involvement.¹⁴

IGCM is a pathologic diagnosis (see Fig. 14-15 *A* and 14-15 *B*). A diffuse or multifocal inflammatory infiltrate consists of lymphocytes admixed with eosinophils and multinucleated giant cells. Myocyte damage must be evident in association with the inflammatory lesion.¹⁵ Various degrees of fibrosis may be present.¹² Poorly formed granulomas may be seen in giant cell myocarditis, but well-organized follicular granulomas containing central giant cells exclude the diagnosis by definition. The lesions of active lymphocytic myocarditis may occasionally contain an isolated giant cell; nonetheless, giant cell myocarditis can usually be distinguished from lymphocytic myocarditis and granulomatous myocarditis, even on biopsy specimens (Table 17-1).

The differential diagnosis of IGCM includes drug reactions and systemic diseases (Table 17-2). Drug hypersensitivity reaction may manifest as IGCM, with evidence of hypersensitivity in other organs.^{16,17} IGCM has been described after high-dose interleukin-2 treatment for lymphoma,¹⁸ possibly as a result of cytokine imbalance. Giant cell myocarditis has been described in a case of measles myocarditis.¹⁹

Up to 20% of cases of giant cell myocarditis occur in individuals with other inflammatory or autoimmune disorders, especially inflammatory bowel disease (Table 17-3).²⁰⁻²⁶ Interestingly, a small percentage of patients who present with giant cell myocarditis at

Table 17-1
Pathologic Findings in Giant Cell Myocarditis, Cardiac Sarcoidosis,
and Lymphocytic Myocarditis

Diagnosis	Definition	Gross pathology	Microscopic pathology	Comments
Giant cell myocarditis*	Widespread or serpiginous inflammation with myocyte necrosis in the absence of well-formed granulomas or specific etiology	Pale, flabby myocardium; dilation or hypertrophy may be present; treated cases may have extensive scar	Widespread or serpiginous inflammation with giant cells, lymphocytes, and often eosinophils; myocyte necrosis always present; poorly formed granulomas may be seen	See Tables 17-2 and 17-3 and text for differential diagnosis and associated disorders
Cardiac sarcoidosis†	Granulomatous myocarditis with no evidence of infectious or other specific cause	Sharply defined areas of granulomatous inflammation or scar; preferential involvement of papillary muscles, septum, and base of ventricles	Non-necrotizing granulomas, fibrosis with few eosinophils; myocyte necrosis is rare	Look for other organ involvement, anergy to common antigens, and ACE level to support diagnosis; exclude fungi, mycobacteria, and foreign body reaction with special studies
Lymphocytic or idiopathic myocarditis‡	A predominantly lymphocytic infiltrate with associated myocyte damage in the absence of acute infarction	Focal or diffuse inflammatory lesions	First pathologic specimen may be active or borderline myocarditis, the latter having no myocyte damage; subsequent samples may be persistent, healing, or healed per "Dallas criteria"	Associated with coxsackie B, adenoviral, and hepatitis C viral infections; biopsy artifacts may resemble myocyte necrosis; rule out many specific causes

ACE, angiotensin-converting enzyme.

*Cooper et al. *N Engl J Med* 1997;336:1860-1866; Davies et al. *Br Heart J* 1975;37:192-195.

†Roberts et al. *Am J Med* 1977;63:86-108.

‡Bloom, editor. *Diagnostic Criteria for Cardiovascular Pathology*, 1997, p 365; Aretz et al. *Am J Cardiovasc Pathol* 1987;1:3-14.

From Cooper LT Jr. Giant cell myocarditis: diagnosis and treatment. *Herz* 2000;25:291-298.

By permission of Urban & Vogel.

Table 17-2
Disorders That May Resemble Giant Cell Myocarditis

Disorder	Associated findings and diagnostic studies	
Sarcoidosis	Granulomatous myocarditis without specific cause; fibrosis may be prominent; myocyte necrosis is rare	Anergy to common antigens; angiotensin-converting enzyme level; look for other organ involvement
Wegener granulomatosis	Granulomatous myocarditis; renal and upper and lower respiratory disease are generally present; vasculitis may affect the coronary arteries	c-ANCA, look for classic renal and respiratory findings
Foreign body reaction	Giant cells may be associated with myocardial reaction to pacemaker leads or ventricular-assist devices	
Hypersensitivity myocarditis	Diffuse, primarily interstitial infiltrate with numerous eosinophils; myocyte necrosis and giant cells are infrequent	Elevated liver function results, eosinophil count, and skin rash
Cardiac lymphoma	Hodgkin disease rarely reported with myocardial granulomas with giant cells*	Immunophenotyping, look for extracardiac involvement
Fungal myocarditis	Coccidioidomycosis, blastomycosis, actinomycosis, and others from granulomas; seen in immunocompromised hosts, often with associated endocarditis or sepsis	Special stains such as Grocott methenamine silver and periodic acid-Schiff indicated
Measles	Rare complication of measles; may cause myocyte necrosis and giant cell myocarditis	Associated clinical findings
Syphilis	Gumma may rarely involve the myocardium; myocardial involvement is rarely isolated	Associated clinical findings; VDRL
Tuberculosis	Nodular, miliary, and diffuse infiltrative types; myocardial involvement is rarely isolated	Other organ involvement; PPD skin test
Rheumatic carditis	Interstitial granulomatous infiltrate without myocyte necrosis in active lesion	Jones criteria [†]

c-ANCA, antineutrophil cytoplasmic antibodies; PPD, purified protein derivative; VDRL, Venereal Disease Research Laboratory.

*Saphir O. Arch Pathol 1942;33:88.

[†]JAMA 1992;268:2069-2073.

From Cooper LT Jr. Giant cell myocarditis: diagnosis and treatment. Herz 2000;25:291-298. By permission of Urban & Vogel.

Table 17-3
Disorders Associated With Idiopathic Giant Cell Myocarditis

Inflammatory disorders
Ulcerative colitis ^{24,26}
Crohn disease ¹⁵
Orbital & skeletal myositis ²⁷
Myasthenia gravis ^{22,28}
Thyroiditis ^{13,29,30}
Takayasu arteritis ^{31,32}
Rheumatoid arthritis ³³
Pernicious anemia ²³
Alopecia totalis vitiligo ³⁴
Tumors
Thymoma ^{28,35}
Lung carcinoma ²⁹
Lymphoma ^{36,37}
Sarcoma ¹³
Hypersensitivity reaction
Silicone rubber ³⁸
Antiseizure medication ¹⁷
Miscellaneous
Post-mitral valve surgery ³⁹
Mitral stenosis-associated ⁴⁰

From Cooper LT Jr. Giant cell myocarditis: diagnosis and treatment. *Herz* 2000;25:291-298.
 By permission of Urban & Vogel.

autopsy or explantation have clinically unrecognized granulomatous inflammation in other organs, including the aorta, lungs, liver, and lymph nodes.⁴¹ These cases suggest that IGCM can be the prime manifestation of a systemic granulomatous process. In our experience, several patients with fatal IGCM have had a granulomatous infiltrate in the lymph nodes or other organs. Therefore, the diagnosis of sarcoidosis or the presence of granulomatous infiltration in other organs does not exclude IGCM.^{13,42}

Disorders that cause myocardial granulomas with associated giant cells may be mistaken for IGCM. Aschoff lesions of rheumatic myocarditis evolve into characteristic, focal interstitial granulomas with giant cells. Tuberculosis and cryptococcosis may also have giant cells within granulomatous lesions.⁴³⁻⁴⁵ Special stains for organisms should be performed whenever there is a question of infection. Rarely, giant cells may be seen in syphilitic myocarditis.⁴⁵ Foreign body reaction, Wegener granulomatosis,^{46,47} and systemic sarcoidosis must be considered in the differential diagnosis as well. These disorders usually

have distinct clinical presentations and appropriate diagnostic studies usually prevent confusion with IGCM.

The tumor most commonly associated with giant cell myocarditis is thymoma, particularly the spindle cell type.¹³ Myasthenia gravis and myositis are associated with thymoma and giant cell myocarditis individually and in combination.^{20,22,27,31,48-52} The association of thymoma with giant cell myocarditis occurs almost exclusively in women.²⁸ IGCM once occurred 10 days after surgical resection of thymoma.³⁵ It has been postulated in the absence of direct evidence that alterations in immune function associated with thymoma predispose to giant cell myocarditis.²² Associations with sarcoma arising from the thymus¹³ and lymphoma³⁶ have also been described; however, lymphoproliferative disease of the heart may be difficult to distinguish from giant cell myocarditis if myocyte necrosis is present.

The incidence of giant cell myocarditis is low and varies with the population studied and method of diagnosis. In a Japanese autopsy registry, the incidence of giant cell myocarditis was 0.007% (25 of 377,841 cases from 1958 to 1977).⁵³ The incidence of giant cell myocarditis was a similarly low 3 of 12,815 necropsies from 1950 to 1963 at Oxford Infirmary.¹¹ The incidence is higher when all IGCM cases diagnosed by endomyocardial biopsy or other surgical specimens, explanted heart, and autopsy are included. Using all pathologic specimens, 5 large, heart failure referral centers in the United States encountered a case of giant cell myocarditis about every 21 months from 1993 to 1997 (Giant Cell Myocarditis Registry, unpublished data).

Until recently, no easily available source of authoritative information on IGCM has been maintained. In 2001, the Web site www.gcm.info.org was established to provide such a resource for affected individuals and their families. This site also provides links to other relevant sites concerned with inflammatory heart disease.

MECHANISMS OF GIANT CELL MYOCARDITIS

The cause of human giant cell myocarditis is not known but often presumed to be autoimmune. Useful data supporting an autoimmune mechanism come from the Lewis rat model of IGCM. Experimental IGCM can be produced in the Lewis rat by autoimmunization with myosin.⁵⁴ In this model, autoimmune giant cell myocarditis is mediated by CD4⁺ T cells that produce interferon- γ and macrophages that produce tumor necrosis factor and nitric oxide.⁵⁵ The disease can be transferred by T lymphocytes.⁵⁶ The histologic changes and hemodynamic deterioration are associated with inducible nitric oxide synthetase expression and attenuated by aminoguanidine, an inhibitor of inducible nitric oxide synthetase.⁵⁷ The detrimental effect of nitric oxide in this model contrasts with the

beneficial effects of nitric oxide in coxsackie viral myocarditis.⁵⁸ Also of interest, tumor necrosis factor- α stimulates multinucleation of macrophages into giant cells *in vitro* when it is secreted from macrophages, but not when it is added exogenously.⁵⁹

Strain differences in rats with experimental giant cell myocarditis suggest that genetic factors play a major role in susceptibility to disease. Shioji and colleagues⁶⁰ reported the incidence, histopathology, and histocompatibility characteristics of 5 inbred strains of rats in which myocarditis was induced with porcine cardiac myosin. Immune-mediated myocarditis was induced in Lewis, Dahl (DIR/Eis) (RT-1), and Fisher rats but not in brown Norway rats or a second strain of Dahl rats (DIS/Eis) (RT-1). The disease was most severe in the Lewis rats and seemed to correlate with major histocompatibility complex class II region differences between the strains. Although 90% of cases in the Giant Cell Myocarditis Registry occurred in whites, firm conclusions regarding ethnic susceptibility cannot be drawn because these data may reflect the populations at the referral centers.¹⁵

Observations in human tissue suggest that IGCM is mediated by T lymphocytes as well.¹² In studies of paraffin-embedded tissue, infiltrating lymphocytes are almost always positive for T-cell antigens and giant cells are positive for macrophage antigens.^{26,61,62} The T-cell subsets (helper and suppressor ratios) may vary during the evolution of the infiltrate. Electron microscopy has failed to find viral particles or other clues to the etiology of giant cell myocarditis.⁶²⁻⁶⁴

Data from the rat model of IGCM support aggressive immunosuppressive treatment early in the disease. Data from the rat model suggest that anti-T-lymphocyte antibodies and cyclosporine, but not prednisolone alone, prevent giant cell myocarditis.⁶⁵⁻⁶⁷ From these observations, immunosuppression with muromonab-CD3 and cyclosporine would be a reasonable treatment for patients who have giant cell myocarditis.

DIAGNOSTIC STRATEGY

The diagnosis of giant cell myocarditis should be considered for all patients with subacute heart failure of unknown cause. Of the 63 Multicenter Giant Cell Myocarditis Registry patients,¹⁵ 75% presented with congestive heart failure, 14% presented with ventricular arrhythmia, and lesser percentages presented with a syndrome mimicking acute myocardial infarction, heart block, or arterial embolization. The median time from symptom onset to presentation was 3 weeks. The median age was 42 years (range, 15 to 69 years), but patients younger than 15 years⁶⁸ and older than 70 years¹¹ have been reported. Men and women are affected equally, and cases have been described in many ethnic groups.

Common causes for heart failure and arrhythmia ought to be excluded per standard clinical practice. After a complete history, physical examination, electrocardiogram, and

chest radiograph, an echocardiogram is usually done to exclude valvular and pericardial disease and cardiac masses. There are no specific echocardiographic findings to distinguish giant cell myocarditis from other forms of myocarditis, although the rapid decline in ejection fraction that may occur over several days in giant cell myocarditis patients is uncommon in lymphocytic myocarditis or cardiac sarcoidosis. Coronary angiography is superior to noninvasive stress imaging to exclude significant coronary stenosis or dissection. Magnetic resonance imaging or computed tomography may be done if clinically indicated to help exclude such disorders as arrhythmogenic right ventricular dysplasia or constrictive pericarditis.

Endomyocardial biopsy ought to be considered for patients with heart failure or ventricular arrhythmia of less than 3 months' duration who fail to improve despite optimal medical care. In most cases of lymphocytic myocarditis, the left ventricular ejection fraction improves with usual care,⁶⁹ whereas the ejection fraction in giant cell myocarditis rarely improves.⁷⁰ The development of ventricular tachycardia or heart block further increases the likelihood of giant cell myocarditis.^{15,70,71} The presence of associated disorders such as thymoma, myasthenia gravis, myositis, or inflammatory bowel disease (Table 17-3) may provide valuable clues as well.

Because giant cell myocarditis usually affects the endocardium,¹² right ventricular endomyocardial biopsy may have a high sensitivity. In a substudy analysis of Giant Cell Myocarditis Registry subjects, Shields et al.⁷² found that endomyocardial biopsy had 82% to 85% sensitivity for giant cell myocarditis compared to the standard of surgical pathology (autopsy, explanted heart, or apical wedge section). This compares favorably to the roughly 35% sensitivity of endomyocardial biopsy in lymphocytic myocarditis, a more common but generally less severe and widespread process.⁷³ However, the Shields et al. study included only subjects who had both endomyocardial biopsy and surgical specimens (ie, selected those with a particularly poor prognosis). The sensitivity of endomyocardial biopsy would likely be lower in an unselected population of heart failure subjects with giant cell myocarditis.

Sampling error is a concern in endomyocardial biopsy, and a minimum of 5 and sometimes more specimens ought to be obtained. Occasionally, the diagnostic lesion is seen only on additional cuts of the specimen blocks. Care must be taken to exclude hypersensitivity myocarditis, granulomatous myocarditis, foreign body reaction, and potential infectious causes by using standard diagnostic criteria and appropriate special stains.⁷⁴ Once the diagnosis of giant cell myocarditis is certain, then one can consider the use of immunosuppressive agents in addition to usual care.

Other diagnostic techniques that have been suggested for viral myocarditis or cardiac sarcoidosis have not been applied to giant cell myocarditis. For example, antibodies to cardiac myosin have been described for patients with acute and chronic myocarditis.⁷⁵

Adenoviral and enteroviral DNA have been found in the hearts of patients with viral myocarditis.⁷⁶ Magnetic resonance imaging and newer echocardiographic techniques have been applied for myocarditis and cardiac sarcoidosis⁷⁷ in pilot studies. Nuclear imaging with gallium-67⁷⁸ to detect leukocytes or antimyosin antibodies to detect myocyte necrosis⁷³ has not been used systematically to diagnose giant cell myocarditis. Because of the rarity and severity of giant cell myocarditis, a highly specific noninvasive test would be of great value; however, such a development is unlikely without a much greater understanding of the cause of giant cell myocarditis.

TREATMENT OF GIANT CELL MYOCARDITIS

Giant cell myocarditis is rapidly progressive and frequently requires the concurrent management of congestive heart failure, tachyarrhythmias, heart block, and secondary renal and hepatic insufficiency. Supportive care may include standard pharmacologic therapy for congestive heart failure, a permanent or temporary pacemaker, an implantable cardiac defibrillator, and an intra-aortic balloon pump. The use of these drugs and devices should be dictated by standard clinical practice.

Ventricular-assist devices have been used to bridge the time until patients with giant cell myocarditis have heart transplantation. Ventricular-assist devices have been used successfully as a bridge to transplantation in patients with lymphocytic⁷⁹ or nonspecific myocarditis.⁸⁰ Brilakis et al.⁸¹ reported a series of 9 patients from the Giant Cell Myocarditis Registry, who received ventricular-assist devices. Successful bridging to transplantation in 7 of 9 (78%) is similar to that reported for other recipients of assist devices. Post-transplantation survival of 57% (4 of 7) at 30 days and 29% (2 of 7) at 1 year was unexpectedly low. Poor post-transplantation survival may have been due to poor pre-transplantation condition of the patients. For a patient with giant cell myocarditis, the time to recovery has been bridged successfully with a biventricular Abiomed assist device (personal communication from patient).

Several case reports and the Giant Cell Myocarditis Registry suggest that treatment with certain combinations of immunosuppressants, but not steroids alone, prolongs transplant-free survival.^{15,82-84} The median time to death or cardiac transplantation for all 63 Registry subjects was 5.5 months from onset of symptoms. Seventy percent of affected individuals died or required heart transplantation within 1 year, and the overall rate of death or cardiac transplantation was 89%.^{15,85} Treatment with cyclosporine and steroid sometimes combined with azathioprine or muromonab-CD3 was associated with a median survival of 12.6 months compared with 3.0 months for those not treated with immunosuppressive agents ($P = 0.001$ by log-rank test).¹⁵ No published data exist for the use of

other immunosuppressive agents such as immunoglobulin, cyclophosphamide, tacrolimus, mycophenolate, or antithymocyte globulin for giant cell myocarditis.

These immunosuppressive treatment data must be interpreted cautiously. The data stem from a small registry, not a randomized controlled trial. They are subject to uncontrolled factors that could possibly lead to an observed treatment effect substantially larger than the actual treatment effect. As an example, it is possible that the giant cell myocarditis patients in this registry with longer transplant-free survival times were more likely to receive combined immunosuppression therapy than the patients with shorter times. If so, this would lead to a biased overestimate of the treatment effect.

The risks of aggressive immunosuppression in this setting are considerable. Cyclosporine can cause renal insufficiency, hypertension, liver function abnormalities, hirsutism, and gum enlargement. Muromonab-CD3 can cause profound hypotension, fever, chills, diarrhea, nausea, and vomiting. Long-term use of prednisone can cause osteoporosis and fractures, myopathy, cataracts, and glaucoma. Therefore, these drugs should be used to treat giant cell myocarditis by individuals experienced in their use at specialized centers.

Cardiac transplantation has been used with acceptable morbidity and mortality as a primary therapy for the management of giant cell myocarditis.⁸⁶⁻⁸⁹ Enthusiasm for transplantation was tempered by several reports of post-transplantation recurrence of giant cell myocarditis (Fig. 17-1).⁹⁰⁻⁹³ The 39 Giant Cell Myocarditis Registry patients who underwent heart transplantation had a 71% 5-year survival, despite a 25% post-transplantation histologic recurrence rate on surveillance endomyocardial biopsies. Therefore, overall post-transplantation survival for giant cell myocarditis patients is comparable to survival for patients who receive transplants for cardiomyopathy.⁹⁴

THE GIANT CELL MYOCARDITIS TREATMENT TRIAL

To control for possible bias in the Registry survival data and to investigate the mechanisms of giant cell myocarditis, the multicenter Giant Cell Myocarditis Treatment Trial was organized. This study is a randomized, open-label trial of muromonab-CD3, cyclosporine, and steroids (prednisolone followed by prednisone) versus cyclosporine and steroids for giant cell myocarditis diagnosed by endomyocardial biopsy. The primary efficacy end point is to compare the rate of death, transplantation, and ventricular-assist device placement at 1 year (event-free survival) in the 2 groups. To investigate the mechanism of survival benefit, hemodynamic and immunohistologic assessments will be obtained before treatment and during the study. The secondary efficacy end points include 1) change in left ventricular ejection fraction measured by radionuclide angiography, 2) improvement in myocardial inflammatory infiltrate, and 3) functional status assessed by the Living With Heart Failure

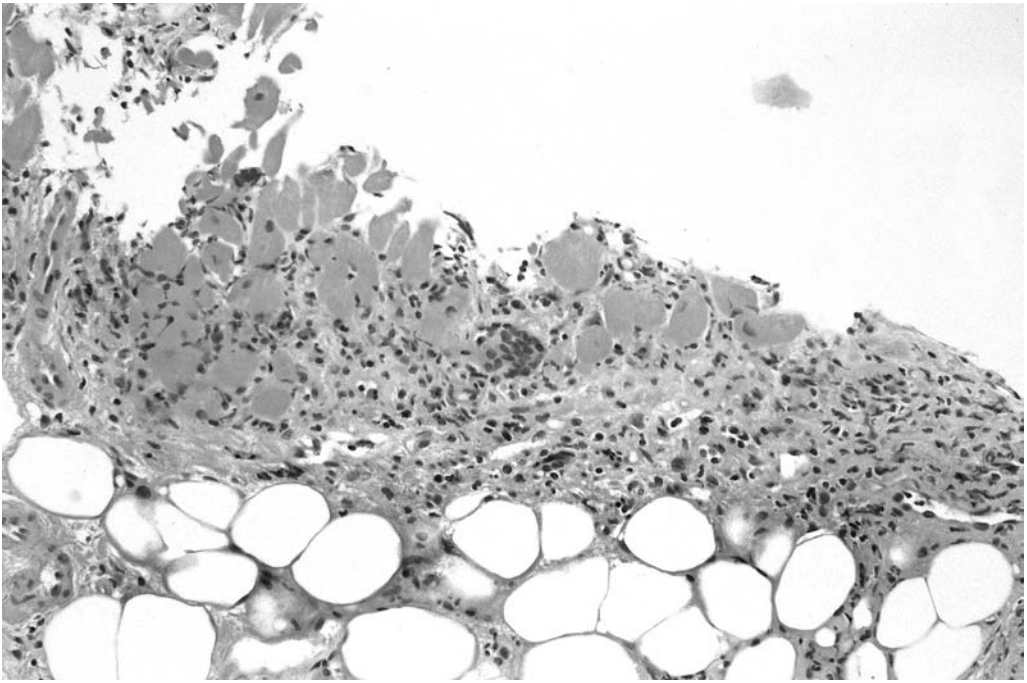


Fig. 17-1. Post-transplantation recurrence of giant cell myocarditis. (Courtesy of Edwina Duhing, MBBS, FRCPA.)

Questionnaire before and after 4 weeks of treatment. Adverse events will be monitored and assessed by an independent safety monitoring committee.

CONCLUSIONS

The prognosis of patients who have giant cell myocarditis is poor, but prolonged transplant-free survival may be possible with aggressive immunosuppression if treatment is started within several months of symptom onset. Because of possible bias in the retrospective Giant Cell Myocarditis Registry survival data and the substantial risks of treatment, the benefits of immunosuppression need to be confirmed in a prospective randomized trial. Consider the diagnosis of giant cell myocarditis for patients with less than 3 months of progressive congestive heart failure or ventricular arrhythmia. Patients with suspected IGCM might be referred to a center involved in the Giant Cell Myocarditis Treatment Trial. Despite a substantial rate of post-transplantation giant cell infiltration on surveillance biopsies, the post-transplantation survival of giant cell myocarditis patients is comparable to post-transplantation survival for cardiomyopathy patients.

REFERENCES

1. Saltykow S. Ueber diffuse Myokarditis. *Virchows Arch Pathol Anat Berl* 1905;182:1-39.
2. Ren H, Poston RS Jr, Hruban RH, Baumgartner WA, Baughman KL, Hutchins GM. Long survival with giant cell myocarditis. *Mod Pathol* 1993;6:402-407.
3. Menghini VV, Savcenko V, Olson LJ, Tazelaar HD, Dec GW, Kao A, Cooper LT Jr. Combined immunosuppression for the treatment of idiopathic giant cell myocarditis. *Mayo Clin Proc* 1999;74:1221-1226.
4. Jonas AF Jr. Granulomatous myocarditis. *Bull Johns Hopkins Hosp* 1939;64:45-65.
5. Saphir O. Myocarditis; general review, with analysis of 240 cases. *Arch Pathol* 1941;32:1000-1051; 1942;33:88-137.
6. Kean BH, Hoekenga MT. Giant cell myocarditis. *Am J Pathol* 1952;28:1095-1105.
7. Bernstein M, Konzelmann FW, Sidlick DM. Boeck's sarcoid; report of case with visceral involvement. *Arch Intern Med* 1929;44:721-734.
8. Scotti TM, McKeown CA. Sarcoidosis involving heart; report of case with sudden death. *Arch Pathol* 1948;46:289-300.
9. Johnson JB, Jason RS. Sarcoidosis of the heart; report of case and review of literature. *Am Heart J* 1944;27:246-258.
10. Tesluk H. Giant cell versus granulomatous myocarditis. *Am J Clin Pathol* 1956;26:1326-1333.
11. Whitehead R. Isolated myocarditis. *Br Heart J* 1965;27:220-230.
12. Litovsky SH, Burke AP, Virmani R. Giant cell myocarditis: an entity distinct from sarcoidosis characterized by multiphasic myocyte destruction by cytotoxic T cells and histiocytic giant cells. *Mod Pathol* 1996;9:1126-1134.
13. Davies MJ, Pomerance A, Teare RD. Idiopathic giant cell myocarditis—a distinctive clinico-pathological entity. *Br Heart J* 1975;37:192-195.
14. Fleming HA. Sarcoid heart disease. *Br Heart J* 1974;36:54-68.
15. Cooper LT Jr, Berry GJ, Shabetai R. Idiopathic giant-cell myocarditis—natural history and treatment. Multicenter Giant Cell Myocarditis Study Group Investigators. *N Engl J Med* 1997;336:1860-1866.
16. Daniels PR, Berry GJ, Tazelaar HD, Cooper LT. Giant cell myocarditis as a manifestation of drug hypersensitivity. *Cardiovasc Pathol* 2000;9:287-291.
17. Ishikawa H, Kaneko H, Watanabe H, Takagi A, Ming ZW. Giant cell myocarditis in association with drug-induced skin eruption. *Acta Pathol Jpn* 1987;37:639-644.
18. Truica CI, Hansen CH, Garvin DF, Meehan KR. Idiopathic giant cell myocarditis after autologous hematopoietic stem cell transplantation and interleukin-2 immunotherapy: a case report. *Cancer* 1998;83:1231-1236.
19. Frustaci A, Abdulla AK, Caldarulo M, Buffon A. Fatal measles myocarditis. *Cardiologia* 1990;35:347-349.
20. Klein BR, Hedges TR III, Dayal Y, Adelman LS. Orbital myositis and giant cell myocarditis. *Neurology* 1989;39:988-990.
21. de Jongste MJ, Oosterhuis HJ, Lie KI. Intractable ventricular tachycardia in a patient with giant cell myocarditis, thymoma and myasthenia gravis. *Int J Cardiol* 1986;13:374-378.
22. Burke JS, Medline NM, Katz A. Giant cell myocarditis and myositis. Associated with thymoma and myasthenia gravis. *Arch Pathol* 1969;88:359-366.
23. Klojin JE. Pernicious anemia and giant cell myocarditis. New association. *Am J Med* 1985;78:355-360.
24. McKeon J, Haagsma B, Bett JH, Boyle CM. Fatal giant cell myocarditis after colectomy for ulcerative colitis. *Am Heart J* 1986;111:1208-1209.

25. Weidhase A, Grone HJ, Unterberg C, Schuff-Werner P, Wiegand V. Severe granulomatous giant cell myocarditis in Wegener's granulomatosis. *Klin Wochenschr* 1990;68:880-885.
26. Ariza A, Lopez MD, Mate JL, Curoso A, Villagrana M, Navas-Palacios JJ. Giant cell myocarditis: monocytic immunophenotype of giant cells in a case associated with ulcerative colitis. *Hum Pathol* 1995;26:121-123.
27. Leib ML, Odel JG, Cooney MJ. Orbital polymyositis and giant cell myocarditis. *Ophthalmology* 1994;101:950-954.
28. Kilgallen CM, Jackson E, Bankoff M, Salomon RN, Surks HK. A case of giant cell myocarditis and malignant thymoma: a postmortem diagnosis by needle biopsy. *Clin Cardiol* 1998;21:48-51.
29. Benisch BM, Josephson M. Subacute (giant cell) thyroiditis and giant cell myocarditis in patient with carcinoma of lung. *Chest* 1973;64:764-765.
30. Burke JS, Medline NM, Katz A. Giant cell myocarditis and myositis: associated with thymoma and myasthenia gravis. *Arch Pathol* 1969;88:359-366.
31. Kennedy LJ Jr, Mitchinson MJ. Giant cell arteritis with myositis and myocarditis. *Calif Med* 1971;115:84-87.
32. Roberts WC, Wubin EA. Idiopathic aortitis, supra-aortic arteritis, granulomatous myocarditis and pericarditis. A case of pulseless disease and possibly left ventricular aneurysm in the African. *Am J Med* 1966;41:453-461.
33. Roberts WC, Kehoe JA, Carpenter DF, Golden A. Cardiac valvular lesions in rheumatoid arthritis. *Arch Intern Med* 1968;122:141-146.
34. Theaker JM, Gatter KC, Brown DC, Heryet A, Davies MJ. An investigation into the nature of giant cells in cardiac and skeletal muscle. *Hum Pathol* 1988;19:974-979.
35. Glennon PE, Petersen ME, Sheppard MN. Fatal giant cell myocarditis after resection of thymoma. *Heart* 1996;75:531-532.
36. Hales SA, Theaker JM, Gatter KC. Giant cell myocarditis associated with lymphoma: an immunocytochemical study. *J Clin Pathol* 1987;40:1310-1313.
37. Helliwell TR, Edwards RH. Giant cell myocarditis associated with lymphoma (letter to the editor). *J Clin Pathol* 1988;41:598-599.
38. Kossovsky N, Cole P, Zackson DA. Giant cell myocarditis associated with silicone. An unusual case of biomaterials pathology discovered at autopsy using x-ray energy spectroscopic techniques. *Am J Clin Pathol* 1990;93:148-152.
39. Rabson AB, Schoen FJ, Warhol MJ, Mudge GH, Collins JJ Jr. Giant cell myocarditis after mitral valve replacement: case report and studies of the nature of giant cells. *Hum Pathol* 1984;15:585-587.
40. Gillie I, Fox H. Mitral stenosis together with a giant cell myocarditis limited to the left atrium. *J Clin Pathol* 1968;21:750-752.
41. Palmer HP, Michael IE. Giant-cell myocarditis with multiple organ involvement. *Arch Intern Med* 1965;116:444-447.
42. Dilling NV. Giant-cell myocarditis. *J Pathol Bacteriol* 1956;71:295-300.
43. Jones I, Nassau E, Smith P. Cryptococcosis of the heart. *Br Heart J* 1965;27:462-464.
44. Diefenbach WCL. Tuberculosis of the heart; review. *Am Rev Tuberc* 1950;62:390-402.
45. Saphir O. Nonrheumatic inflammatory diseases of the heart: C. Myocarditis. In: Gould SE, ed. *Pathology of the heart*. 2nd ed. Springfield, IL: Charles C Thomas, 1960:779-823.
46. Lie JT. Wegener's granulomatosis: histological documentation of common and uncommon manifestations in 216 patients. *Vasa* 1997;26:261-270.
47. McCrea PC, Childers RW. Two unusual cases of giant cell myocarditis associated with mitral stenosis and with Wegener's syndrome. *Br Heart J* 1964;26:490-498.

48. Schmid KO. Granulomatous giant cell polymyositis and myocarditis in benign thymoma. *Verh Dtsch Ges Pathol* 1965;49:248-253.
49. Namba T, Brunner NG, Grob D. Idiopathic giant cell polymyositis. Report of a case and review of the syndrome. *Arch Neurol* 1974;31:27-30.
50. Bourgeois-Droin C, Sauvanet A, Lemarchand F, De Roquancourt A, Cottenot F, Brocheriou C. Thymoma associated with myasthenia, erythroblastopenia, myositis and giant cell myocarditis. One case. *Nouv Presse Med* 1981;10:2097-2098; 2103-2104.
51. Tomimoto H, Akiguchi I, Kameyama M, Haibara H, Kitaichi M. Giant cell myositis and myocarditis associated with myasthenia gravis and thymoma—an autopsy case. *Rinsho Shinkeigaku* 1985;25:688-693.
52. Butany JW, McAuley P, Bergeron C, MacLaughlin P. Giant cell myocarditis and myositis associated with thymoma and leprosy. *Can J Cardiol* 1991;7:141-145.
53. Okada R, Wakafuji S. Myocarditis in autopsy. *Heart Vessels Suppl* 1985;1:23-29.
54. Kodama M, Matsumoto Y, Fujiwara M, Masani F, Izumi T, Shibata A. A novel experimental model of giant cell myocarditis induced in rats by immunization with cardiac myosin fraction. *Clin Immunol Immunopathol* 1990;57:250-262.
55. Okura Y, Yamamoto T, Goto S, Inomata T, Hirono S, Hanawa H, Feng L, Wilson CB, Kihara I, Izumi T, Shibata A, Aizawa Y, Seki S, Abo T. Characterization of cytokine and iNOS mRNA expression in situ during the course of experimental autoimmune myocarditis in rats. *J Mol Cell Cardiol* 1997;29:491-502.
56. Kodama M, Matsumoto Y, Fujiwara M. In vivo lymphocyte-mediated myocardial injuries demonstrated by adoptive transfer of experimental autoimmune myocarditis. *Circulation* 1992;85:1918-1926.
57. Hirono S, Islam MO, Nakazawa M, Yoshida Y, Kodama M, Shibata A, Izumi T, Imai S. Expression of inducible nitric oxide synthase in rat experimental autoimmune myocarditis with special reference to changes in cardiac hemodynamics. *Circ Res* 1997;80:11-20.
58. Badorff C, Fichtlscherer B, Rhoads RE, Zeiher AM, Muelsch A, Dimmeler S, Knowlton KU. Nitric oxide inhibits dystrophin proteolysis by coxsackieviral protease 2A through S-nitrosylation: a protective mechanism against enteroviral cardiomyopathy. *Circulation* 2000;102:2276-2281.
59. Sorimachi K, Akimoto K, Tsuru K, Ieiri T, Niwa A. The involvement of tumor necrosis factor in the multinucleation of macrophages. *Cell Biol Int* 1995;19:547-549.
60. Shioji K, Kishimoto C, Nakayama Y, Sasayama S. Strain difference in rats with experimental giant cell myocarditis. *Jpn Circ J* 2000;64:283-286.
61. Chow LH, Ye Y, Linder J, McManus BM. Phenotypic analysis of infiltrating cells in human myocarditis. An immunohistochemical study in paraffin-embedded tissue. *Arch Pathol Lab Med* 1989;113:1357-1362.
62. Cooper LT Jr, Berry GJ, Rizeq M, Schroeder JS. Giant cell myocarditis. *J Heart Lung Transplant* 1995;14:394-401.
63. Pyun KS, Kim YH, Katzenstein RE, Kikkawa Y. Giant cell myocarditis. Light and electron microscopic study. *Arch Pathol* 1970;90:181-188.
64. Tubbs RR, Sheibani K, Hawk WA. Giant cell myocarditis. *Arch Pathol Lab Med* 1980;104:245-246.
65. Zhang S, Kodama M, Hanawa H, Izumi T, Shibata A, Masani F. Effects of cyclosporine, prednisolone and aspirin on rat autoimmune giant cell myocarditis. *J Am Coll Cardiol* 1993;21:1254-1260.
66. Hanawa H, Kodama M, Inomata T, Izumi T, Shibata A, Tuchida M, Matsumoto Y, Abo T. Anti-alpha beta T cell receptor antibody prevents the progression of experimental autoimmune myocarditis. *Clin Exp Immunol* 1994;96:470-475.

67. Kodama M, Hanawa H, Saeki M, Hosono H, Inomata T, Suzuki K, Shibata A. Rat dilated cardiomyopathy after autoimmune giant cell myocarditis. *Circ Res* 1994;75:278-284.
68. Goldberg GM. Myocarditis of giant-cell type in an infant. *Am J Clin Pathol* 1955;25:510-513.
69. Mason JW, O'Connell JB, Herskowitz A, Rose NR, McManus BM, Billingham ME, Moon TE. A clinical trial of immunosuppressive therapy for myocarditis. The Myocarditis Treatment Trial Investigators. *N Engl J Med* 1995;333:269-275.
70. Davidoff R, Palacios I, Southern J, Fallon JT, Newell J, Dec GW. Giant cell versus lymphocytic myocarditis. A comparison of their clinical features and long-term outcomes. *Circulation* 1991;83:953-961.
71. Okura Y, Dec GW, Hare JM, Berry GR, Tazelaar HD, Cooper LT. A Multicenter Registry comparison of cardiac sarcoidosis and idiopathic giant-cell myocarditis (abstract). *Circulation* 2000;102 Suppl 2:II-788.
72. Shields RC, Tazelaar HD, Berry GJ, Cooper LT. The role of right ventricular endomyocardial biopsy for idiopathic giant cell myocarditis. *J Card Fail* 2002;8:74-78.
73. Narula J, Khaw BA, Dec GW, Palacios IF, Newell JB, Southern JF, Fallon JT, Strauss HW, Haber E, Yasuda T. Diagnostic accuracy of antimyosin scintigraphy in suspected myocarditis. *J Nucl Cardiol* 1996;3:371-381.
74. Bloom S, Lie JT, Silver MD, eds. Diagnostic criteria for cardiovascular pathology: acquired diseases. Philadelphia: Lippincott-Raven Publishers, 1997:365.
75. Lauer B, Padberg K, Schultheiss HP, Strauer BE. Autoantibodies against human ventricular myosin in sera of patients with acute and chronic myocarditis. *J Am Coll Cardiol* 1994;23:146-153.
76. Martin AB, Webber S, Fricker FJ, Jaffe R, Demmler G, Kearney D, Zhang YH, Bodurtha J, Gelb B, Ni J, Bricker JT, Towbin JA. Acute myocarditis. Rapid diagnosis by PCR in children. *Circulation* 1994;90:330-339.
77. Shimada T, Shimada K, Sakane T, Ochiai K, Tsukihashi H, Fukui M, Inoue S, Katoh H, Murakami Y, Ishibashi Y, Maruyama R. Diagnosis of cardiac sarcoidosis and evaluation of the effects of steroid therapy by gadolinium-DTPA-enhanced magnetic resonance imaging. *Am J Med* 2001;110:520-527.
78. Hirose Y, Ishida Y, Hayashida K, Maeno M, Takamiya M, Ohmori F, Miyatake K, Uehara T, Nishimura T, Tachibana T. Myocardial involvement in patients with sarcoidosis. An analysis of 75 patients. *Clin Nucl Med* 1994;19:522-526.
79. Starling RC, Galbraith TA, Baker PB, Howanitz EP, Murray KD, Binkley PF, Watson KM, Unverferth DV, Myerowitz PD. Successful management of acute myocarditis with biventricular assist devices and cardiac transplantation. *Am J Cardiol* 1988;62:341-343.
80. Reiss N, El-Banayosy A, Posival H, Morshuis M, Minami K, Korfer R. Management of acute fulminant myocarditis using circulatory support systems. *Artif Organs* 1996;20:964-970.
81. Brilakis ES, Olson LJ, Daly RC, Cooper LT. Survival outcomes of patients with giant cell myocarditis bridged by ventricular assist devices (abstract). *J Heart Lung Transplant* 1999;18:43.
82. Costanzo-Nordin MR, Silver MA, O'Connell JB, Scanlon PJ, Robinson JA. Giant cell myocarditis: dramatic haemodynamic and histologic improvement with immunosuppressive therapy. *Eur Heart J* 1987;8 Suppl J:271-274.
83. Levy NT, Olson LJ, Weyand C, Brack A, Tazelaar HD, Edwards WD, Hammill SC. Histologic and cytokine response to immunosuppression in giant-cell myocarditis. *Ann Intern Med* 1998;128:648-650.
84. Desjardins V, Pelletier G, Leung TK, Waters D. Successful treatment of severe heart failure caused by idiopathic giant cell myocarditis. *Can J Cardiol* 1992;8:788-792.
85. Cooper LT Jr, Shabetai R. Immunosuppressive therapy for myocarditis (letter to the editor). *N Engl J Med* 1995;333:1713-1714.
86. Scott RL, Ratliff NB, Starling RC, Young JB. Recurrence of giant cell myocarditis in cardiac allograft. *J Heart Lung Transplant* 2001;20:375-380.

Myocarditis: From Bench to Bedside

87. Nieminen MS, Salminen US, Taskinen E, Heikkila P, Partanen J. Treatment of serious heart failure by transplantation in giant cell myocarditis diagnosed by endomyocardial biopsy. *J Heart Lung Transplant* 1994;13:543-545.
88. Briganti E, Esmore DS, Federman J, Bergin P. Successful heart transplantation in a patient with histopathologically proven giant cell myocarditis (letter to the editor). *J Heart Lung Transplant* 1993;12:880-881.
89. Laruelle C, Vanhaecke J, Van de Werf F, Flameng W, Verbeken E, Meyns B, Vermeersch P, De Geest H. Cardiac transplantation in giant cell myocarditis. A case report. *Acta Cardiol* 1994;49:279-286.
90. Kong G, Madden B, Spyrou N, Pomerance A, Mitchell A, Yacoub M. Response of recurrent giant cell myocarditis in a transplanted heart to intensive immunosuppression. *Eur Heart J* 1991;12:554-557.
91. Gries W, Farkas D, Winters GL, Costanzo-Nordin MR. Giant cell myocarditis: first report of disease recurrence in the transplanted heart. *J Heart Lung Transplant* 1992;11:370-374.
92. Grant SC. Giant cell myocarditis in a transplanted heart (letter to the editor). *Eur Heart J* 1993;14:1437.
93. Grant SC. Recurrent giant cell myocarditis after transplantation (letter to the editor). *J Heart Lung Transplant* 1993;12:155-156.
94. Cooper LT, Olson LJ, Berry GJ, Tazelaar H. Post-transplantation survival of patients with idiopathic giant cell myocarditis (GCM) versus cardiomyopathy (CM) (abstract). *J Am Coll Cardiol* 1998;31 Suppl A:251A.